

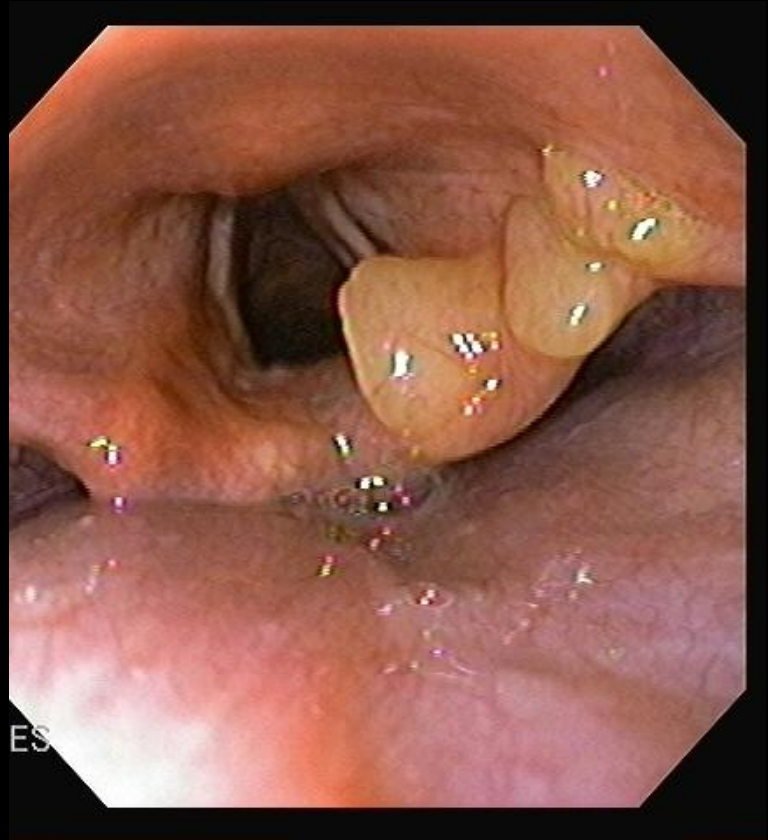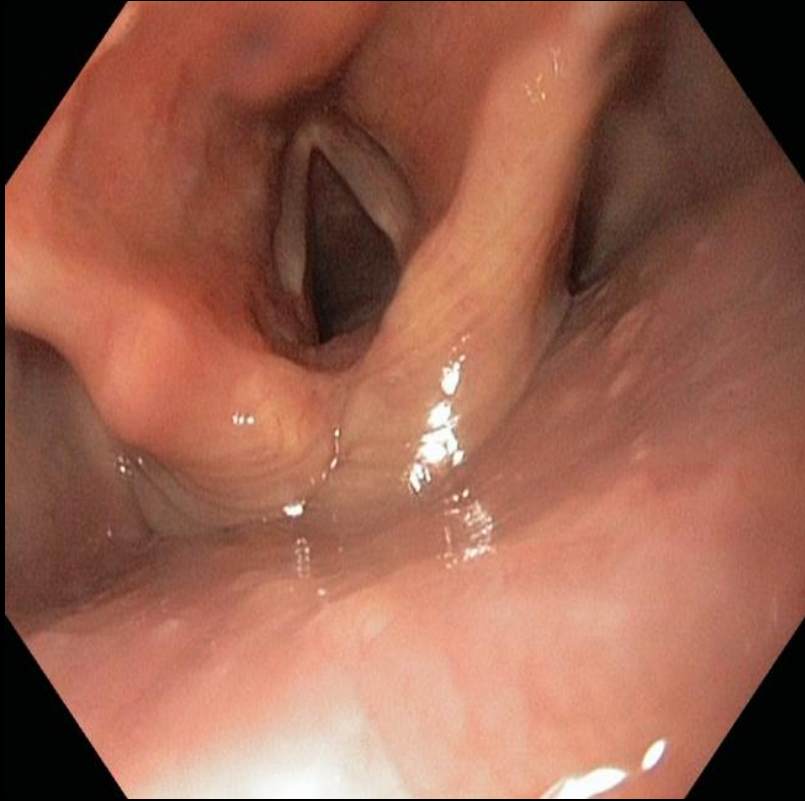Café da Manhã Científico

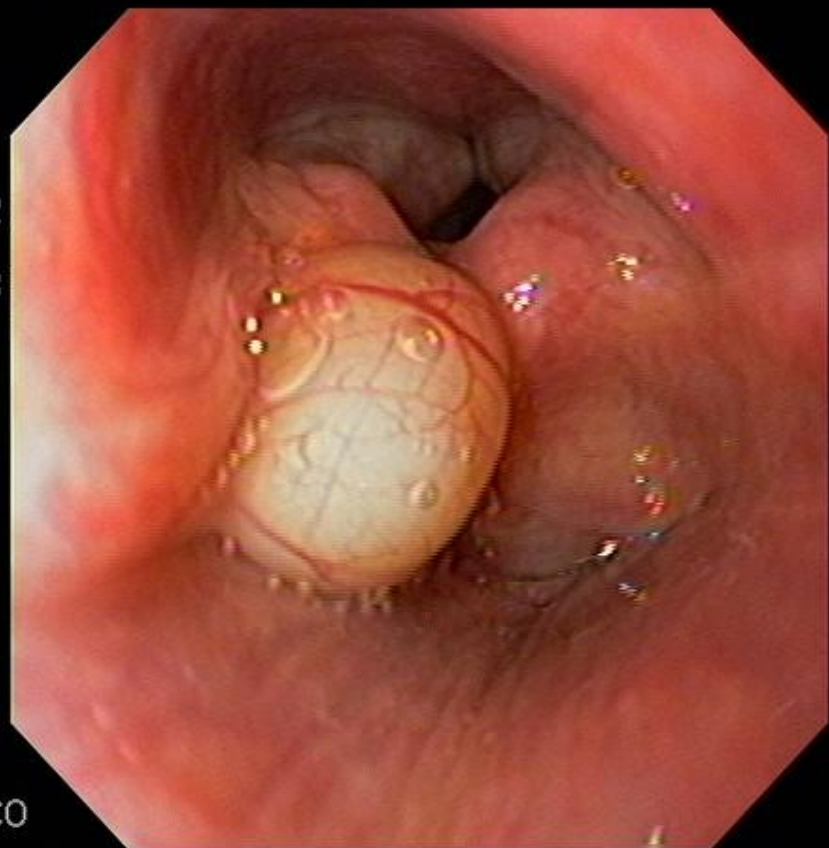
08 de Abril de 2014

MESA REDONDA

“Diagnósticos do Tubo Digestivo”:
Imagens e Métodos Endoscópicas

Dr. Aloisio Carvalhaes





48928
KTY

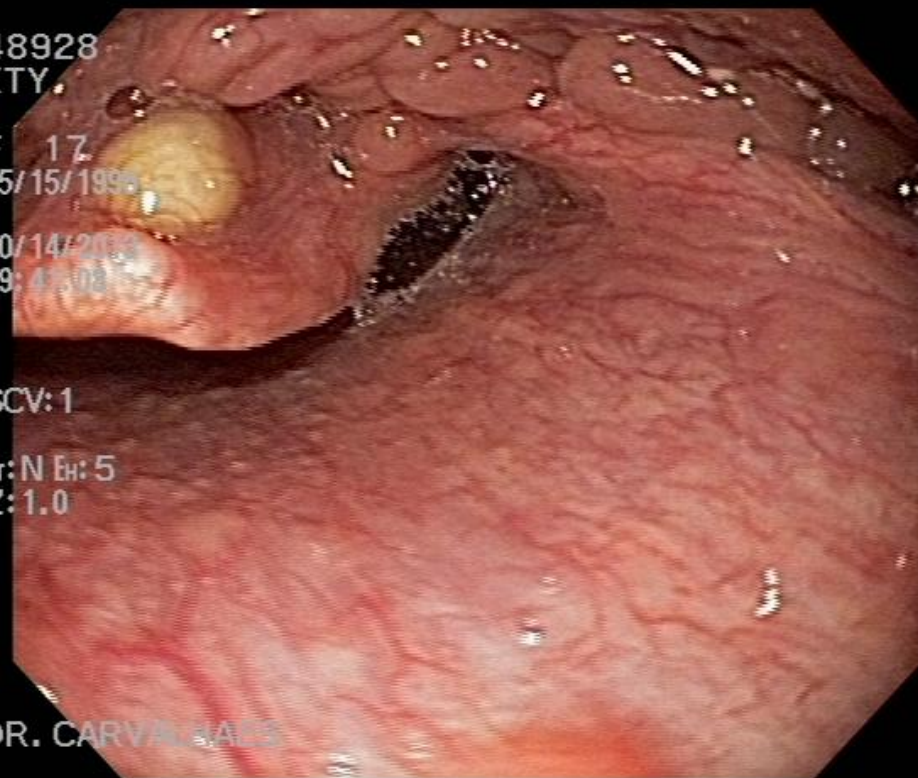F 17
05/15/1996

10/14/2003
09:47:08

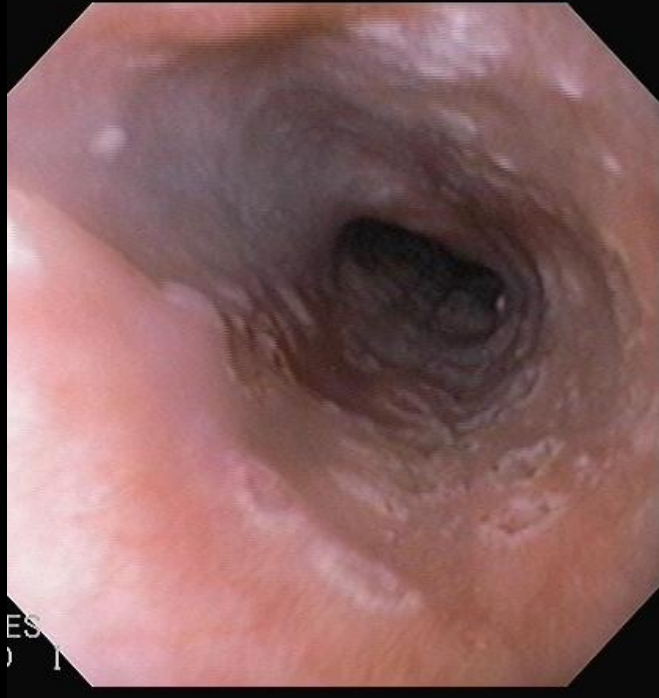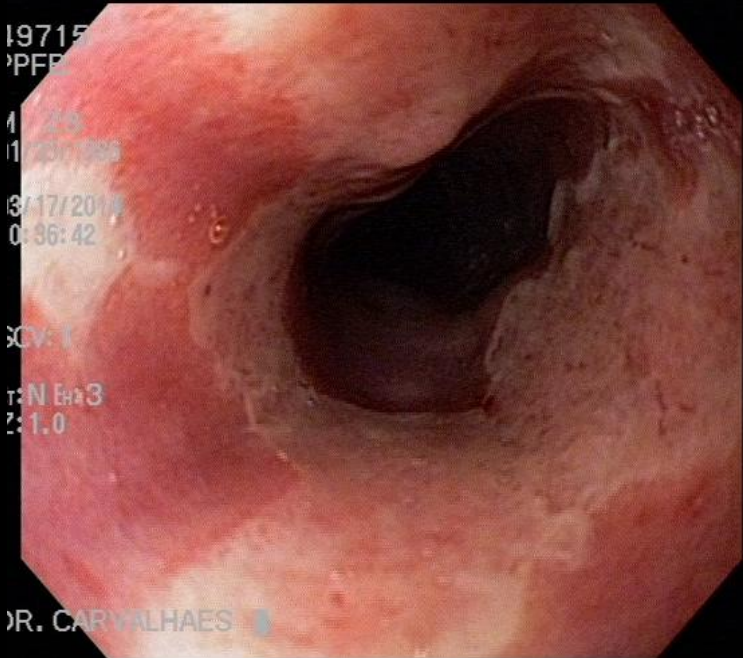
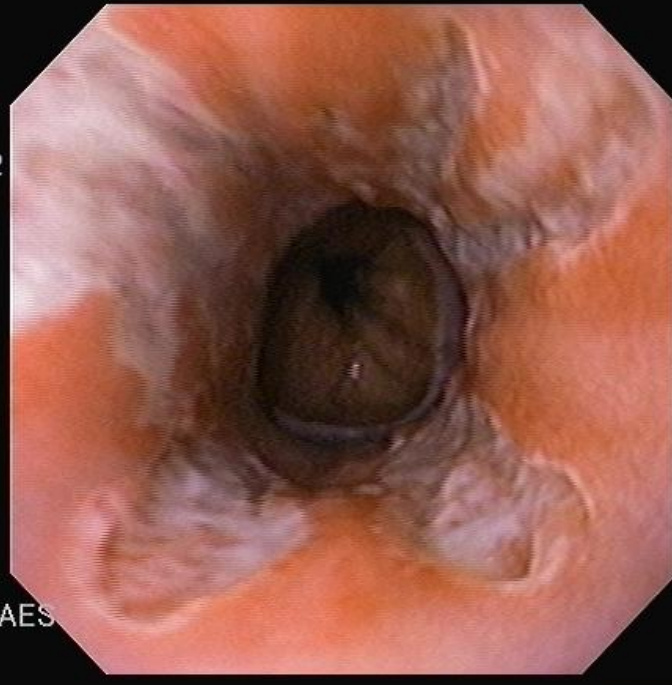
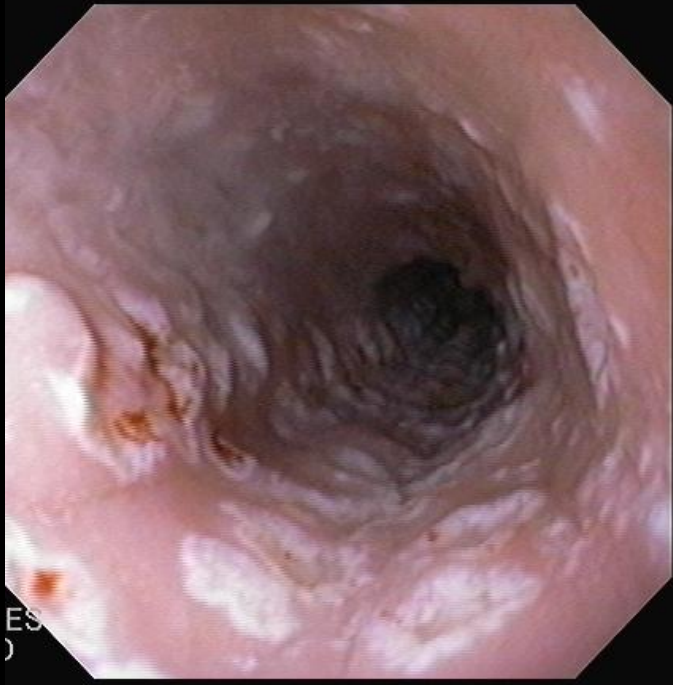SCV: 1

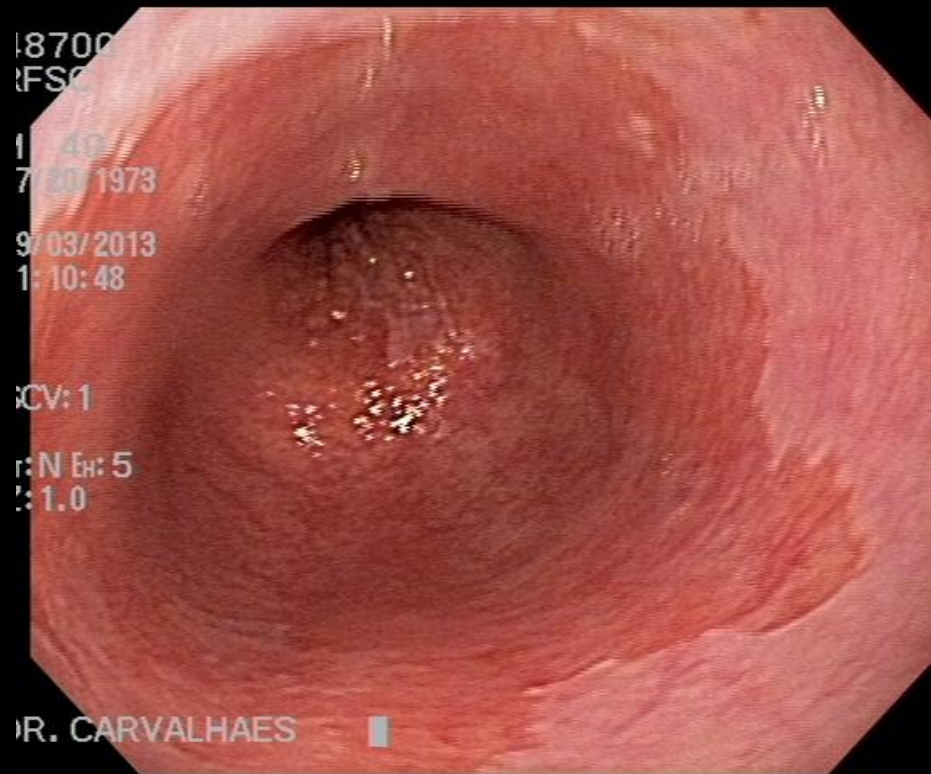
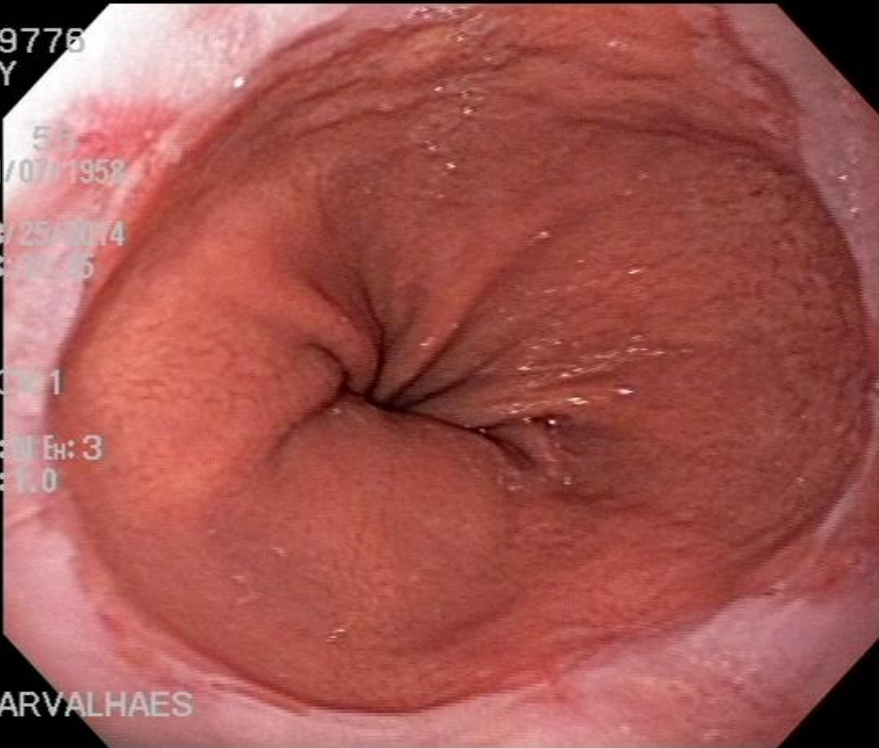
Ct: N Et: 5
Z: 1.0

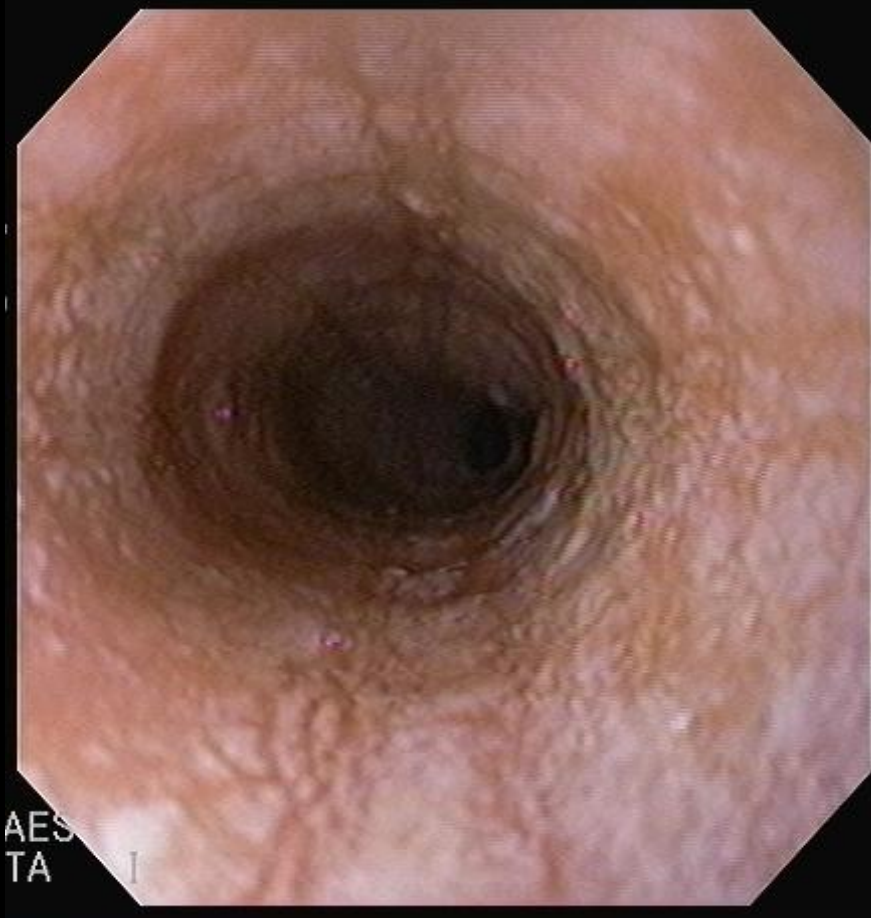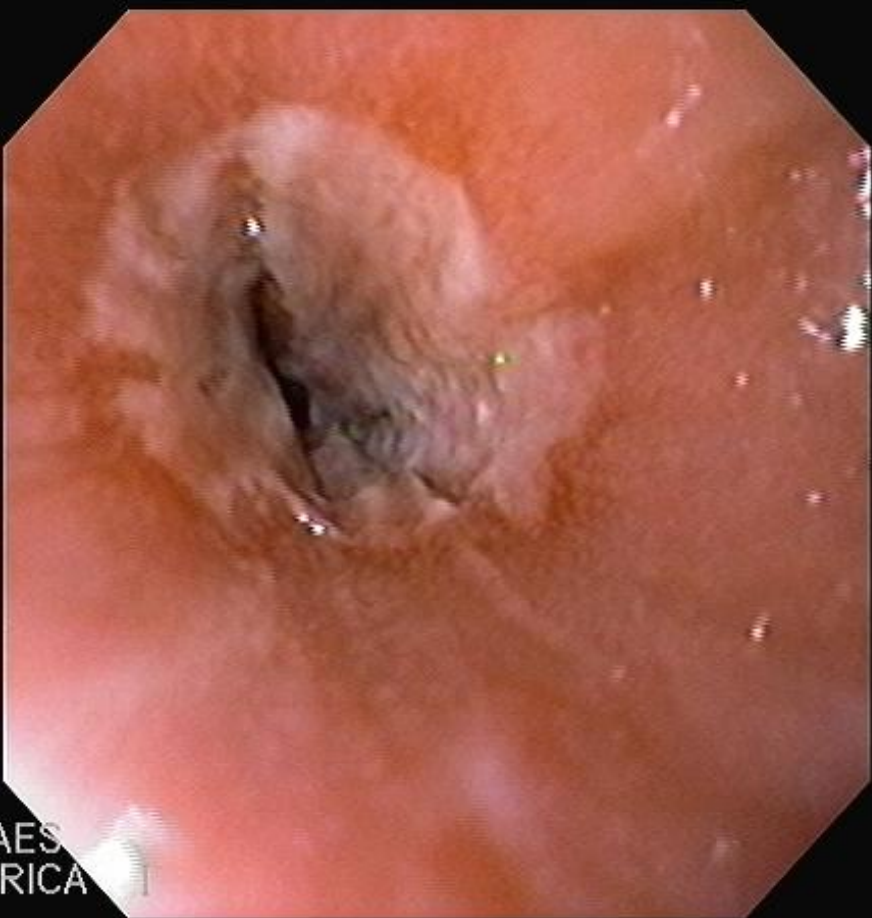DR. CARVALHO

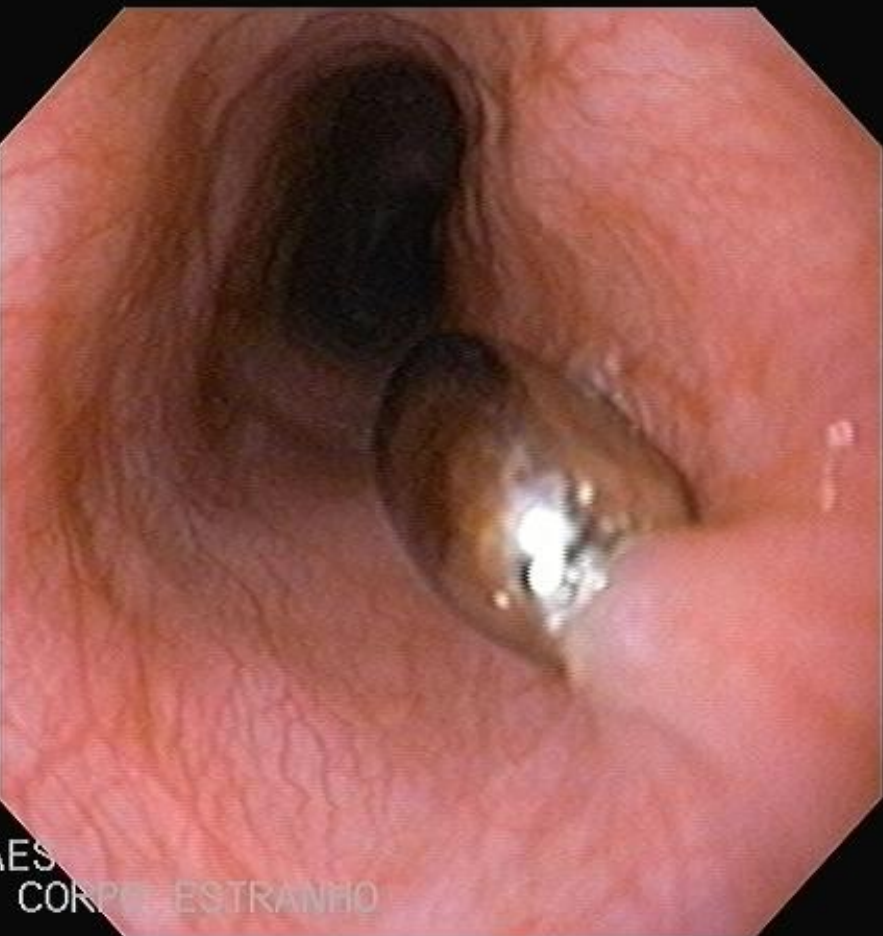

0





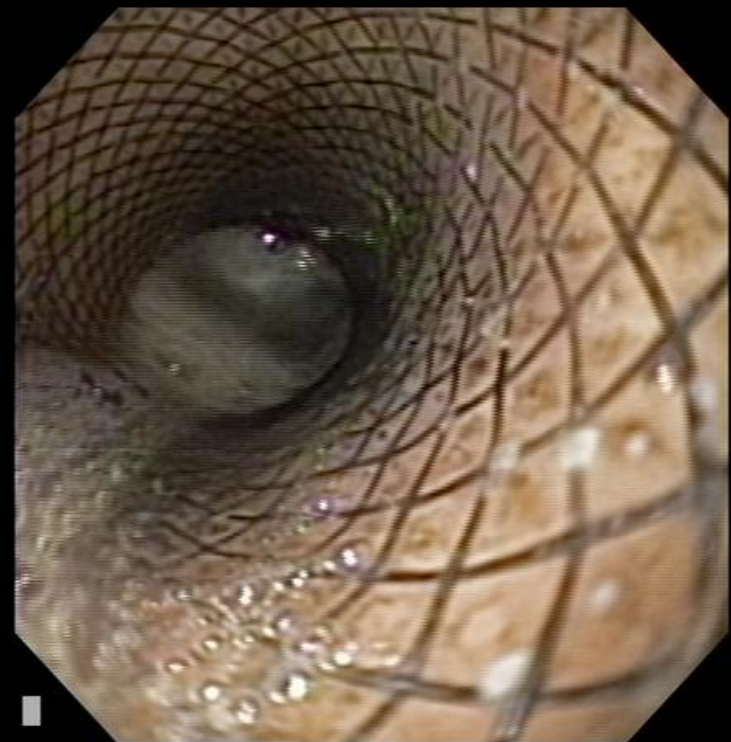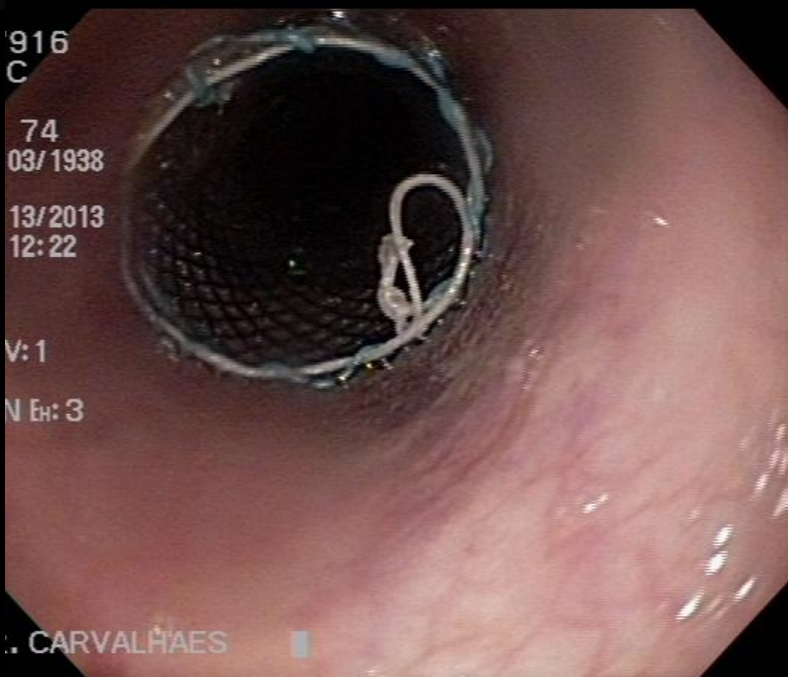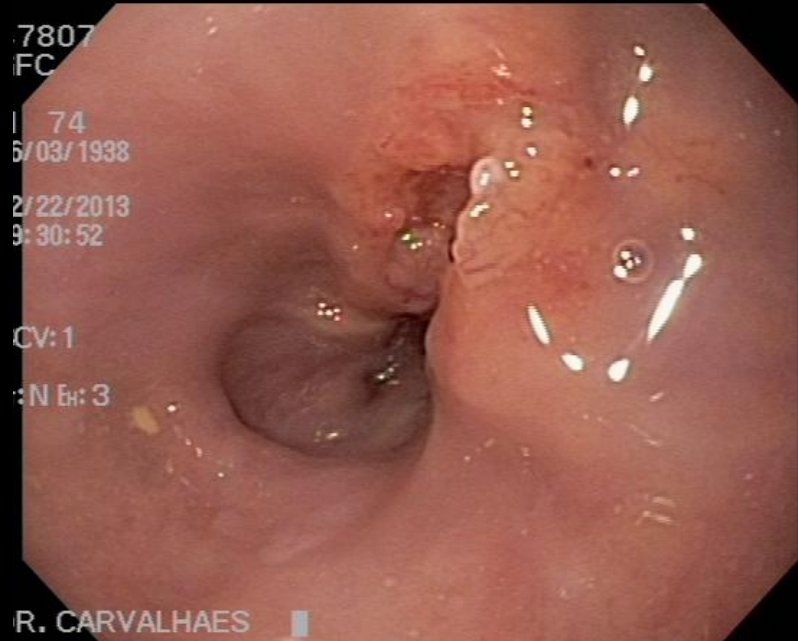


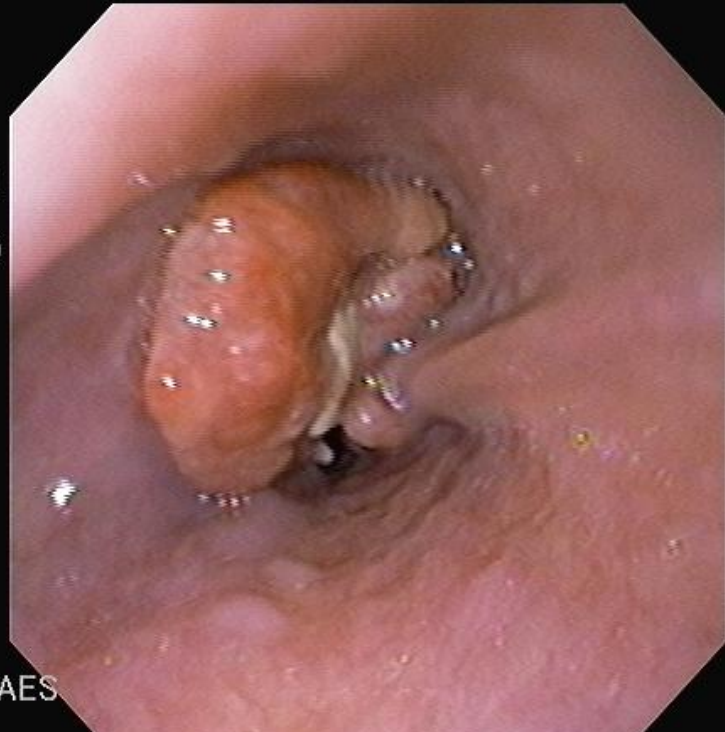

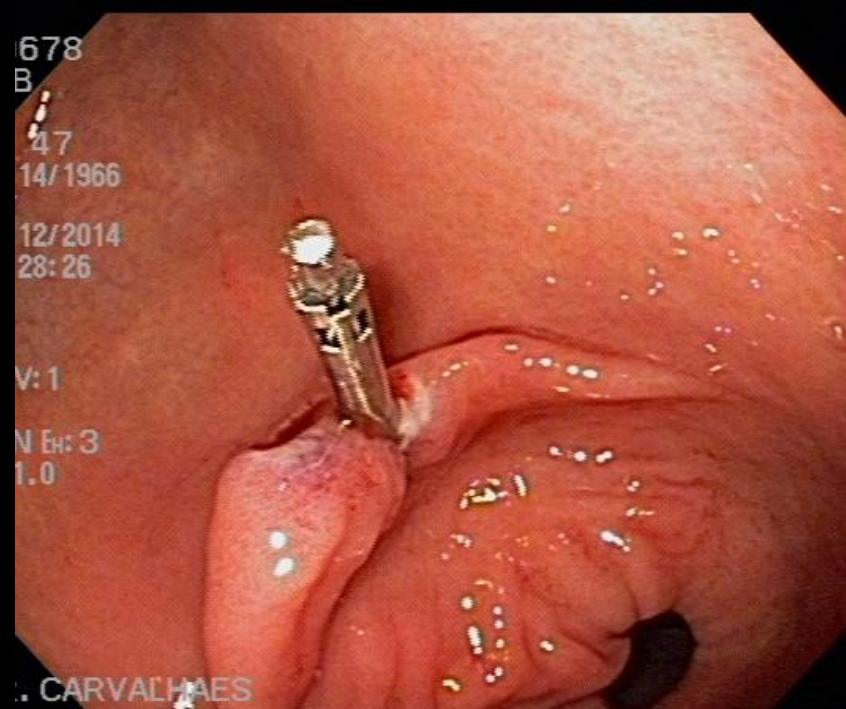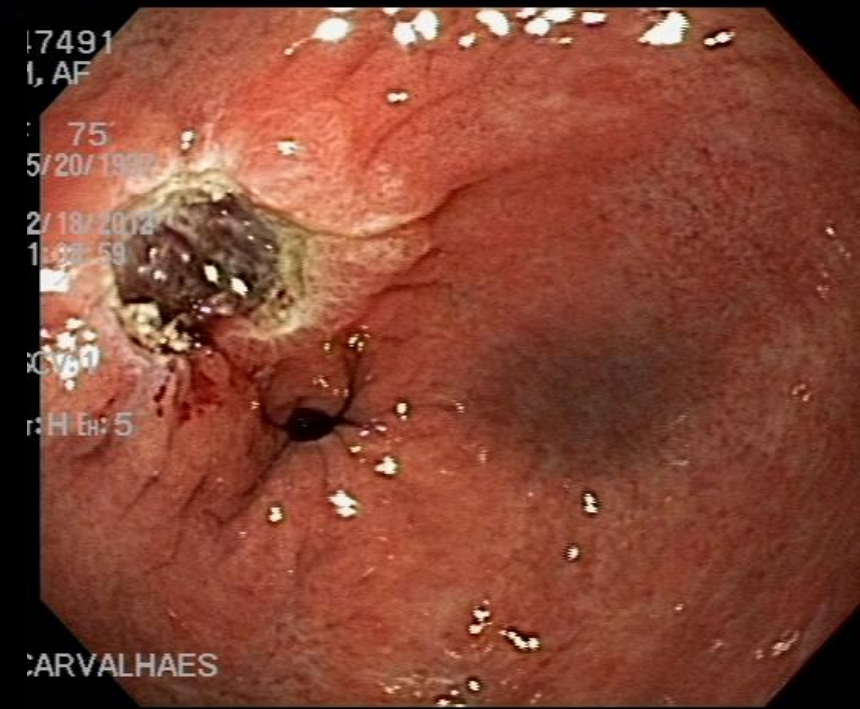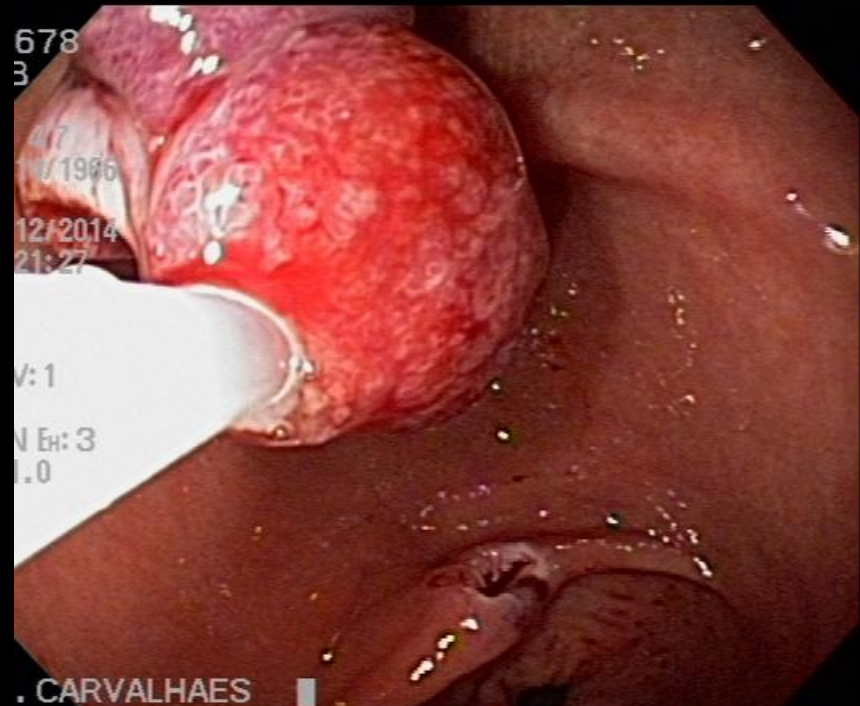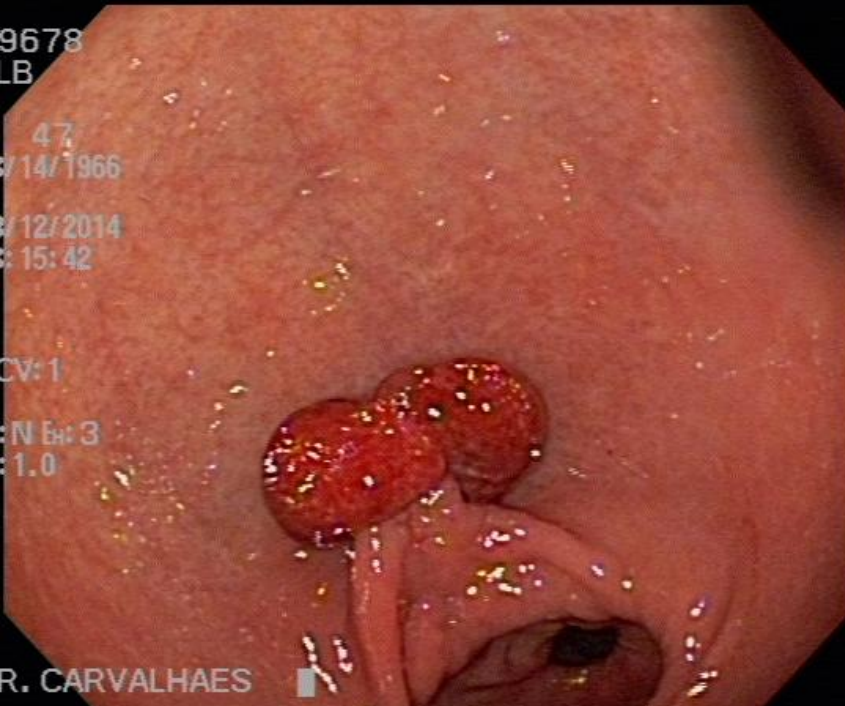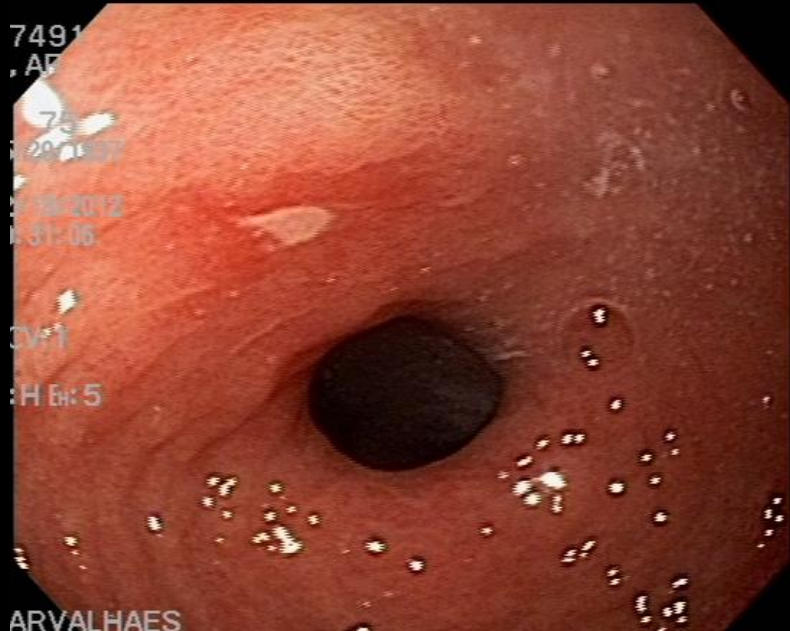ES
CORPO ESTRANHO



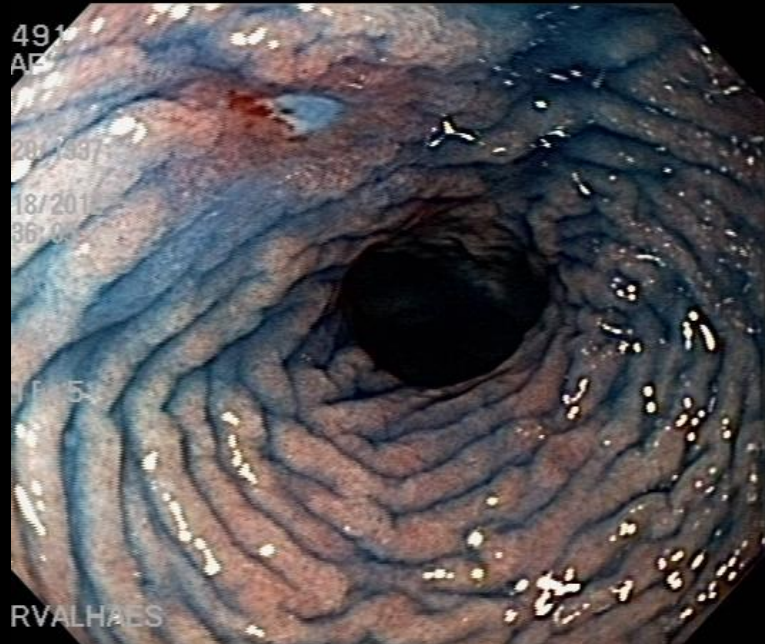ES
CORPO ESTRANHO



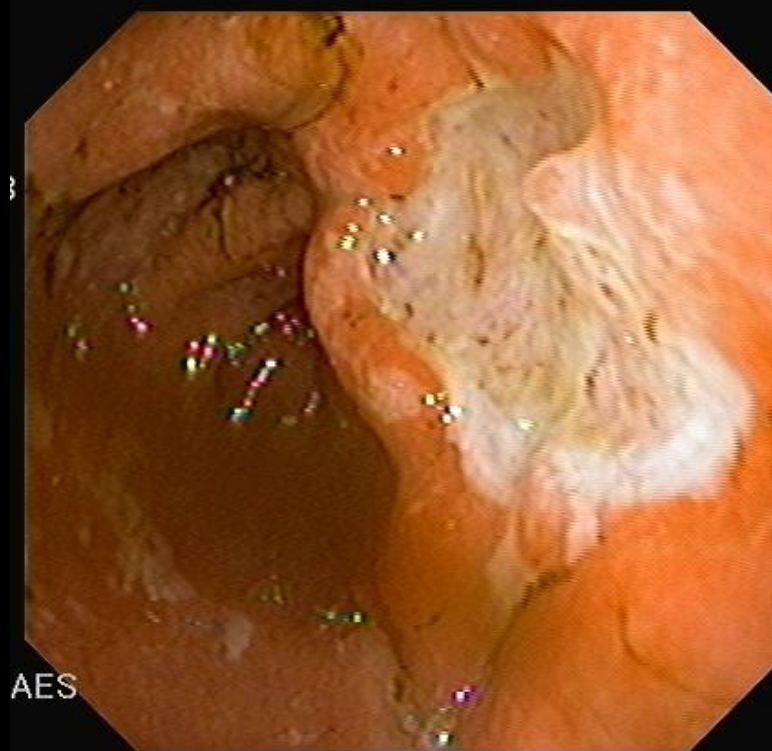




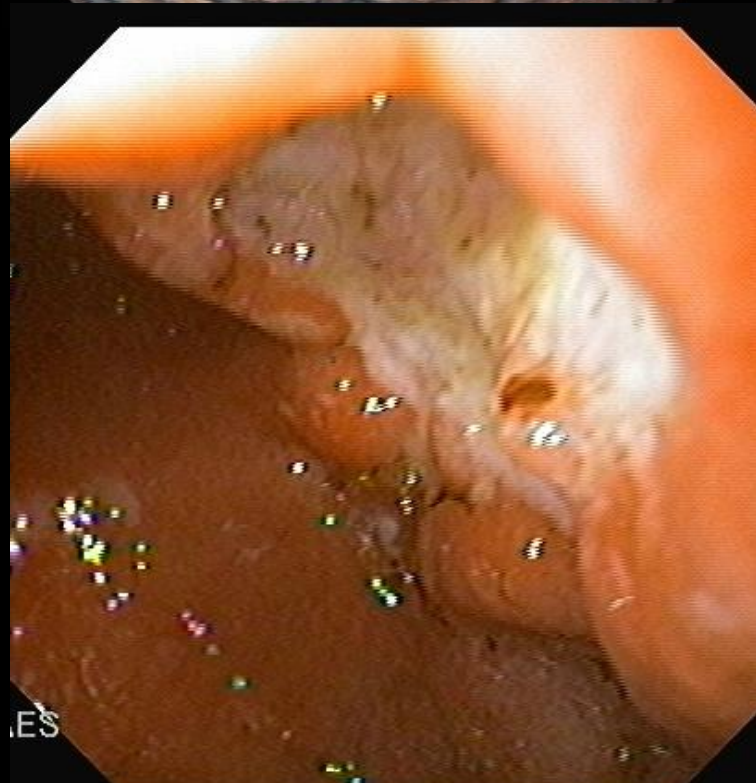
ARVALHAES



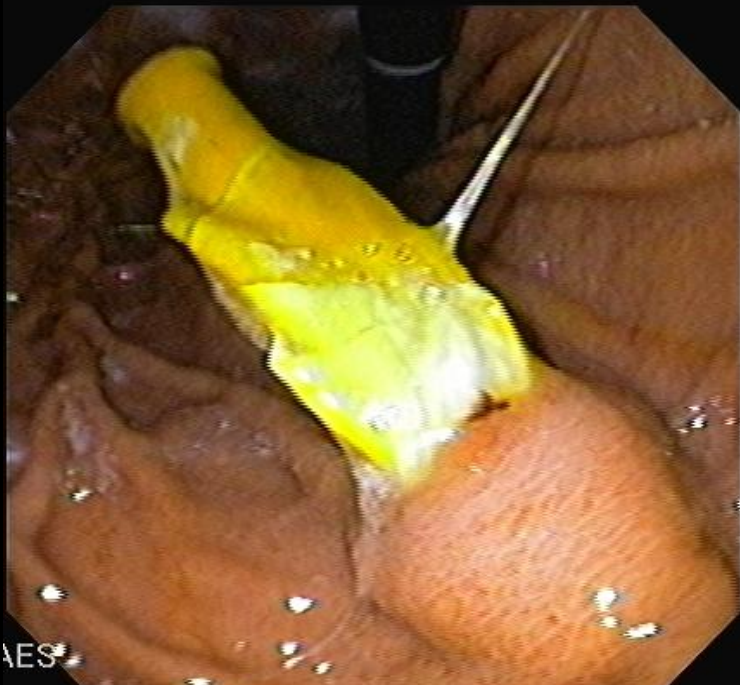
RVALHAES



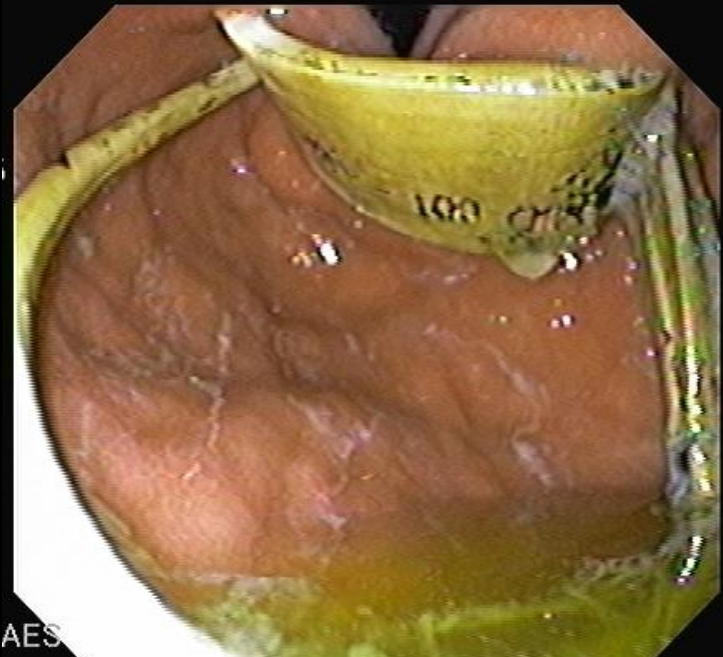
AES



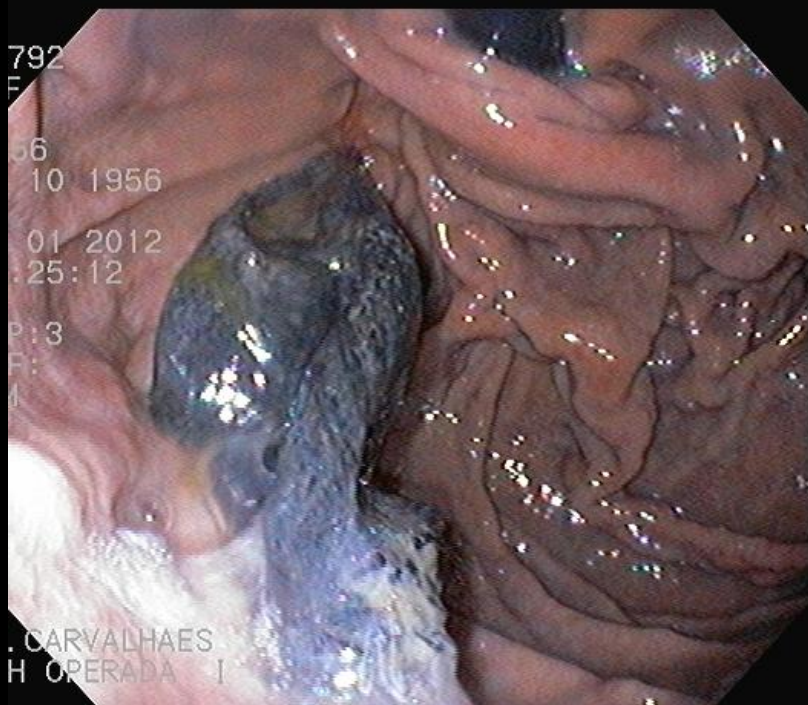
IES



AES

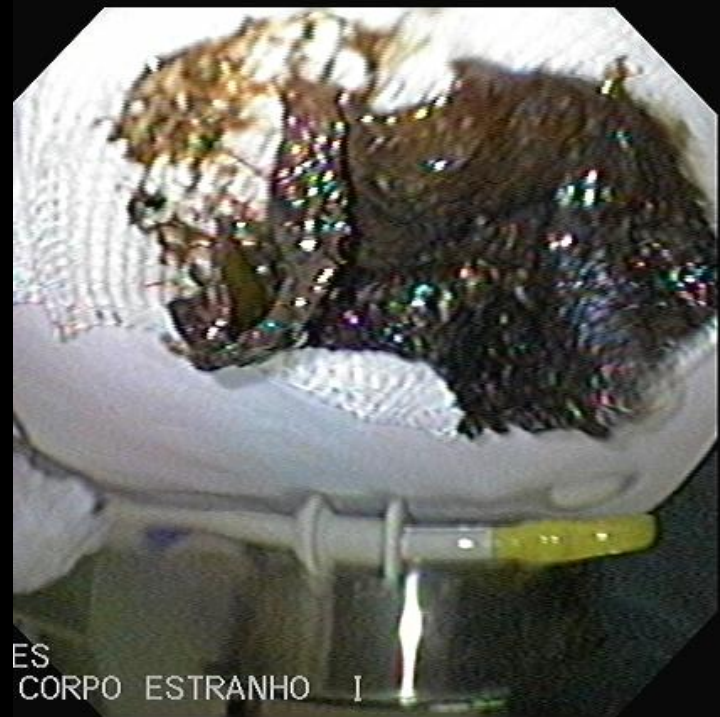


AES



792
F
56
10 1956
01 2012
:25:12
P:3
F:

. CARVALHAES
H OPERADA I



ES
CORPO ESTRANHO I

9675
RFR

39
3/09/1975

3/11/2014
1:22:55

CV: 1
:N Et: 3
:1.0

R. CARVALHAES

32
09

HAES

9722
INA

35
3/14/1979

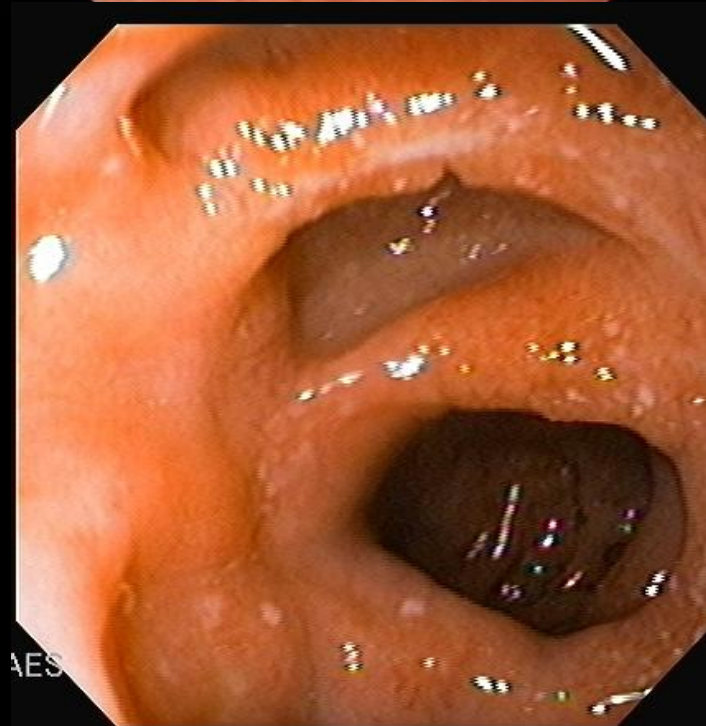
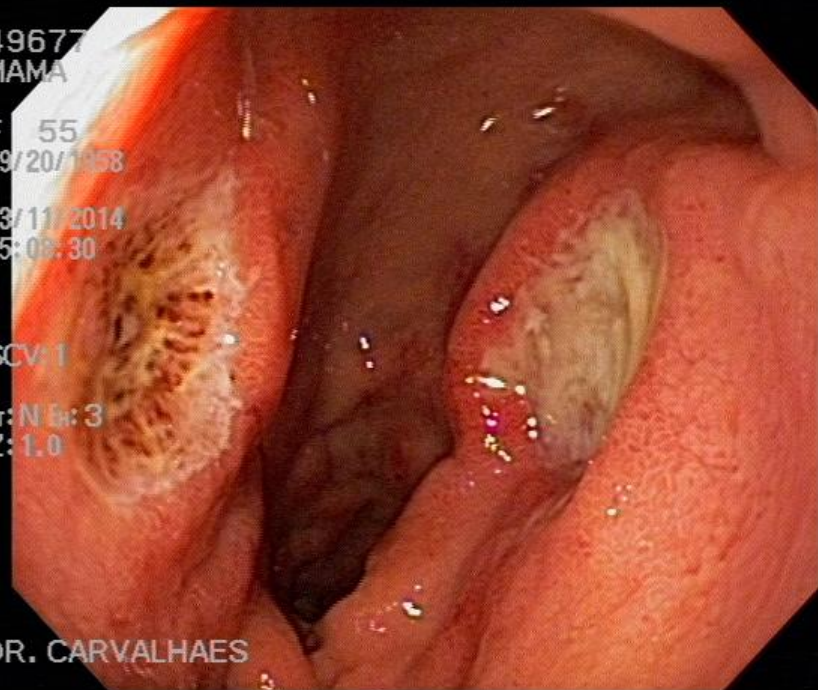
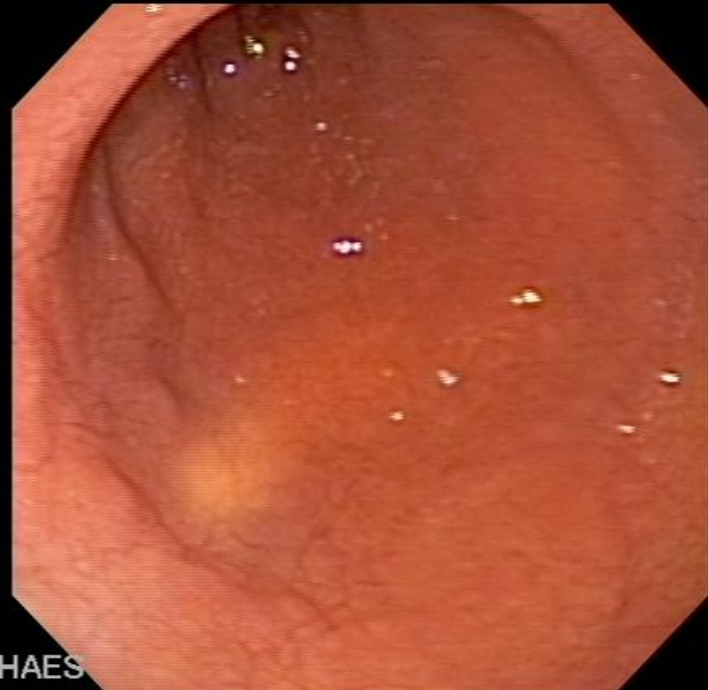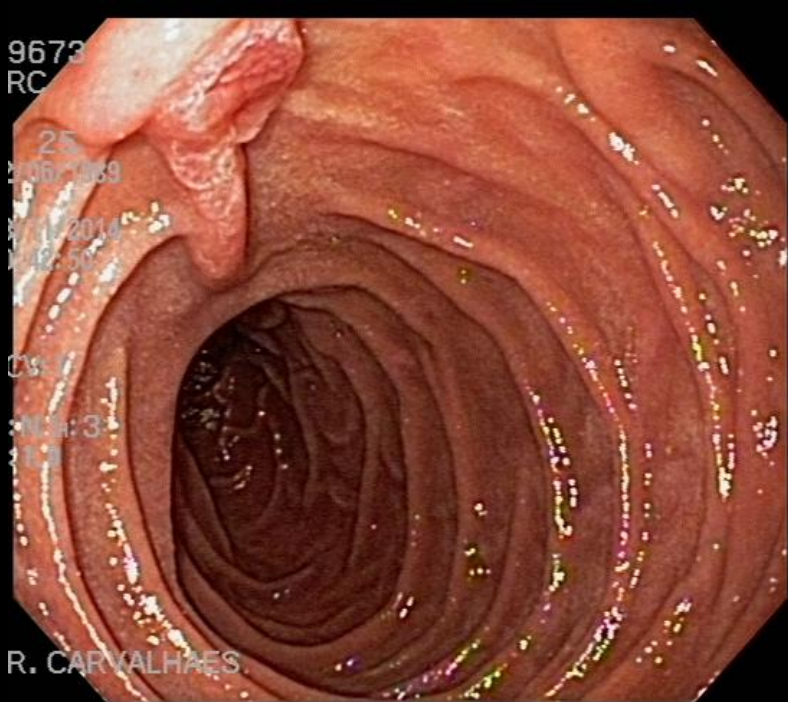3/18/2014
8:51:30

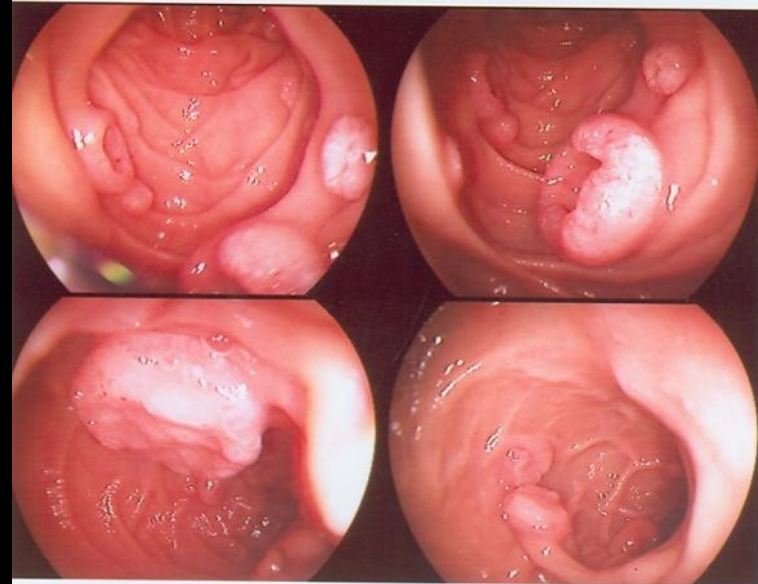
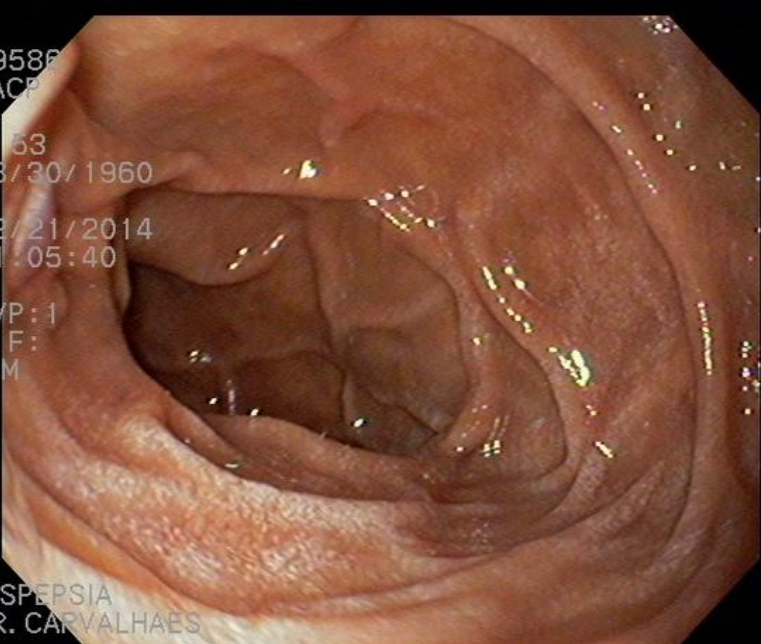CV: 1
:N Et: 3
:1.0

R. CARVALHAES

16881
OSP
70
09 25 1941
08 16 2012
11:26:49

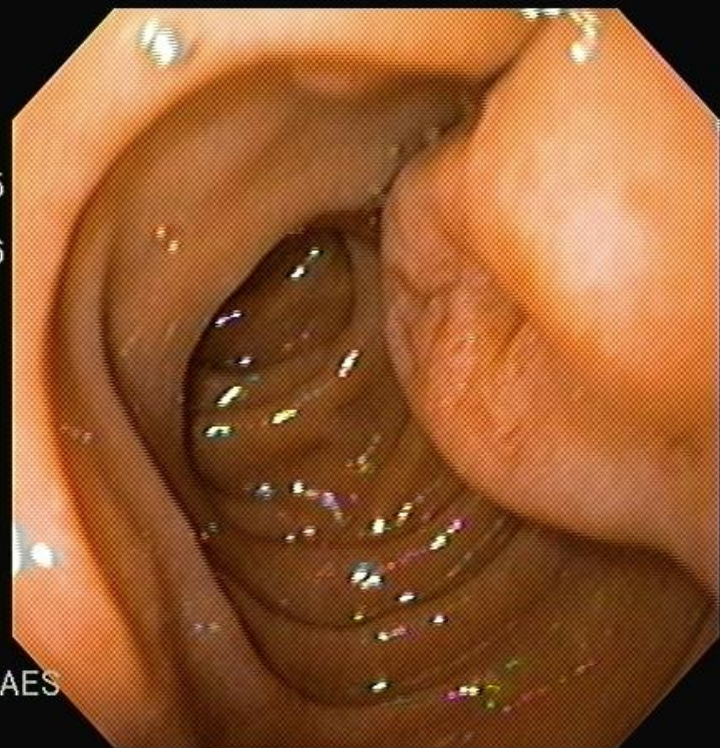R. CARVALHAES
JRGE I



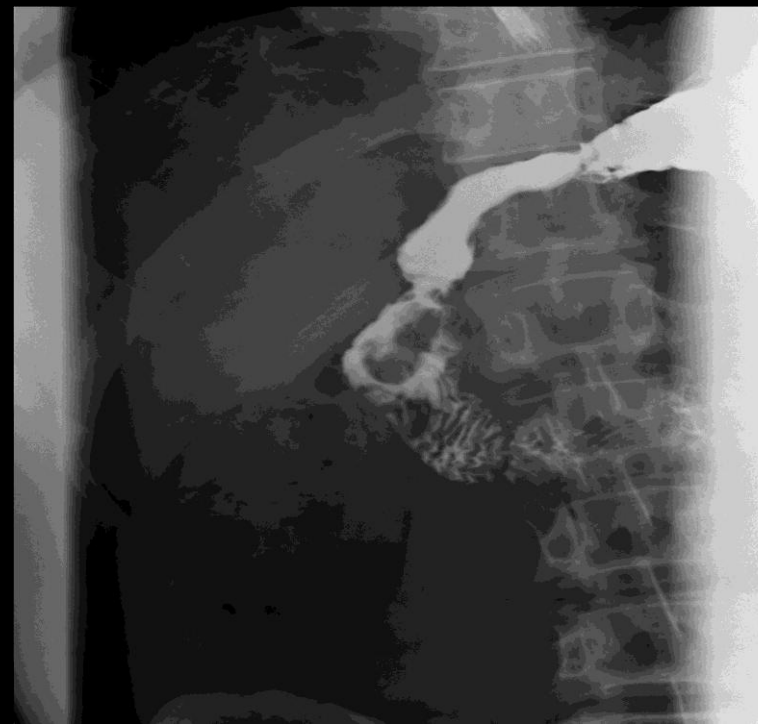

DR CARVALHAES.

MELANOMA



AEES



37377

PM

M 90

10 08 1917

01 04 2008

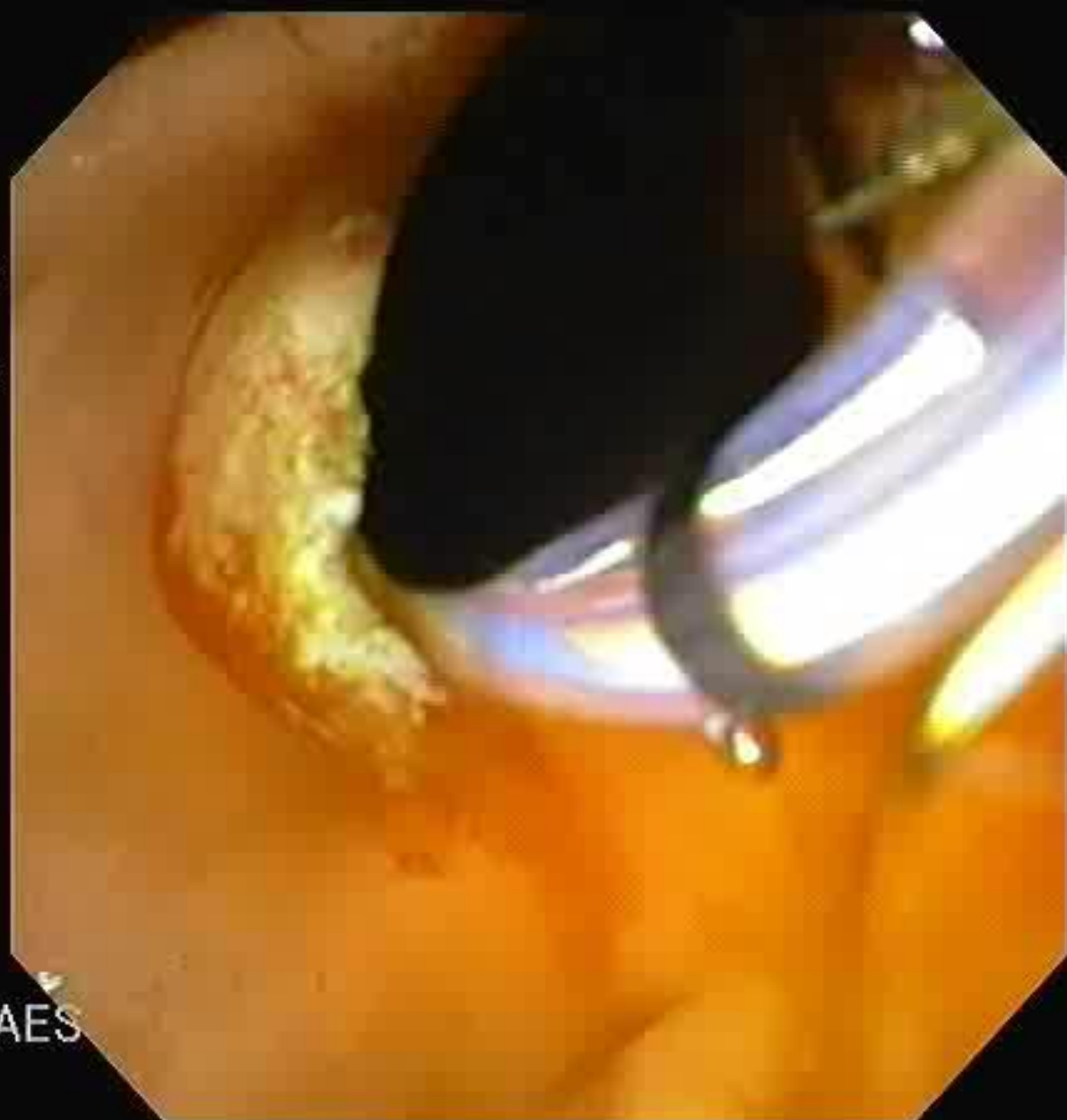13:48:47

CVP: 1

D. F:

Et: M

DR. CARVALHAES
ICTERICIAI



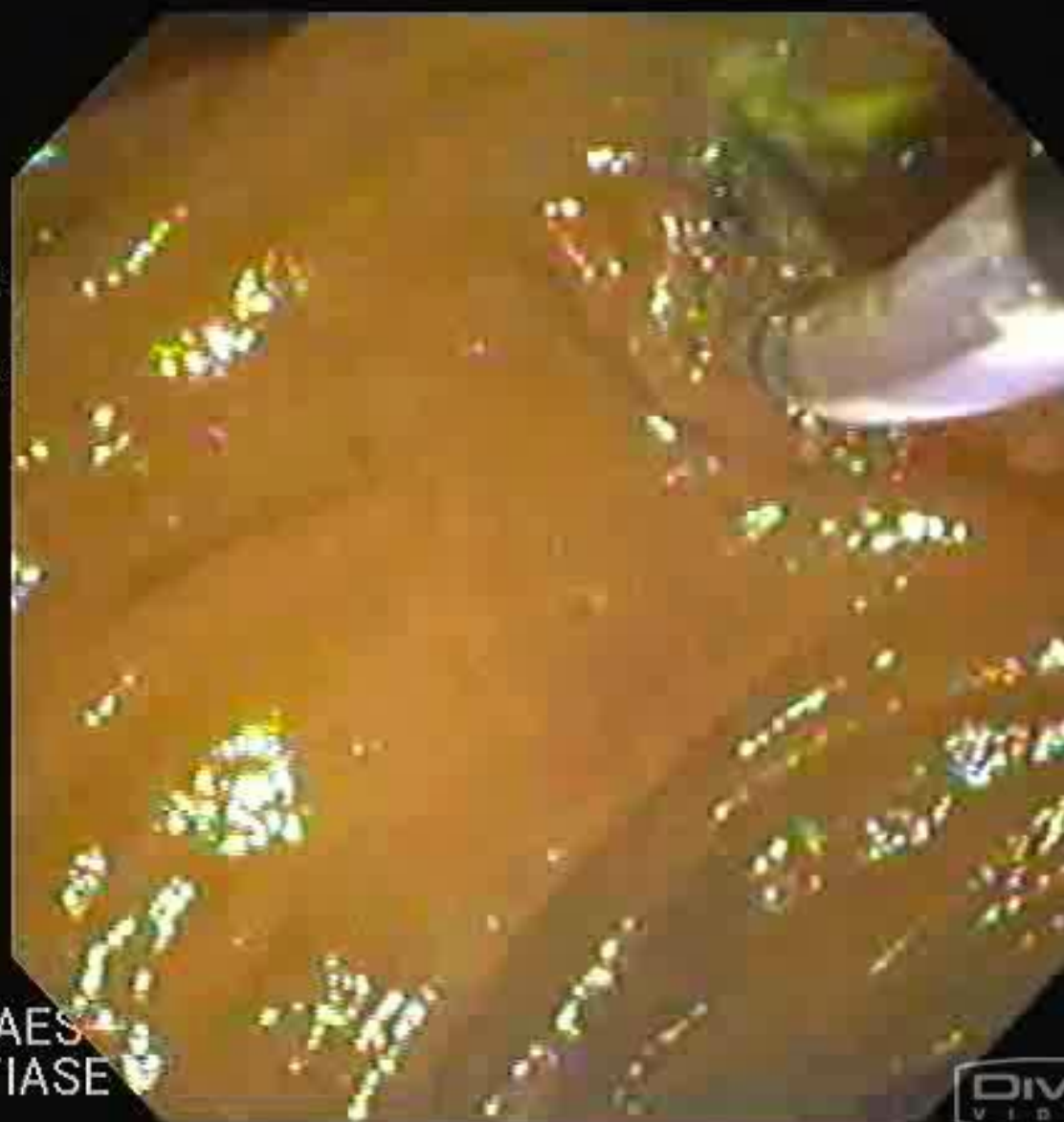
38859
CRSC

F 36
06 10 1972

10 15 2008
17:38:35

CVP: 1
D. F:
Et: M

DR. CARVALHAES
COLEDOCOLITIASE



385471

JP

M 86

01 10 1922

08 15 2008

17:42:35

CVP: 1

D. F:

Et: M

DR. CARVALHAES

ICTERICIA









